

Histopathological Patterns of Testicular Biopsies in Male Infertility

Huma Mushtaq¹, Saeed Alam² and Mumtaz Ahmad Khan³

¹Assistant Professor, Department of Pathology, Islamabad Medical & Dental College, Islamabad

²Professor, Department of Pathology, Islamabad Medical & Dental College, Islamabad

³Professor, Department of Pathology, Foundation University College, Rawalpindi

(^{1,2}Bahria University, Islamabad)

Abstract

Objective: To evaluate histopathological patterns of testicular biopsy specimens from infertile males and to categorize each case according to Modified Johnson scoring system.

Introduction: Male infertility contributes to about 20% of infertility cases. Testicular biopsy is important in categorizing patients with Azoospermia and provides useful information and guidelines for further treatment. Histopathological findings of testicular biopsies are of significant importance in making decision for selection of cases for Intracytoplasmic sperm injection (ICSI) in patients with non obstructive azoospermia.

Methodology: Testicular biopsies from male patients with history of infertility and azoospermia were included in this study. All biopsies were received in 10% formalin fixative and routinely processed and stained with Hematoxylin and Eosin (H and E). Clinical data was obtained and recorded on a proforma. All cases were examined microscopically and various histological patterns were evaluated and categorized according to the histopathological patterns and Modified Johnson scoring was performed.

Results: A total 53 cases of testicular biopsies from azoospermic males were evaluated. Mean age was 28 years and range was from 24- 56 years. Most frequent pattern was of Sertoli cell only syndrome (30.18%), further categorized as Johnson score 2. The second most frequent was hypospermatogenesis (18.86%), further categorized as Johnson score 7. There were 5 cases that showed mixed pattern and 1 case showed discordant pattern.

Conclusion: This study outlines the different histopathological patterns of testicular biopsies in cases of male infertility in our setup and identifies Sertoli cell only syndrome as the most common pathological finding amongst various histopathological patterns.

Key Words: Testicular biopsy, hypospermatogenesis, male infertility

Infertility is defined as inability to conceive after one year of unprotected intercourse.¹ Male infertility is one of the important causes of infertility among couples and it contributes to significant number of infertility cases.² It's a common practice in our social setup to stigmatize only the female partner in cases of infertility, similarly while investigating the causes of infertility concentration is on evaluating female pathologic causes and male conditions are generally ignored and often misdiagnosed. Hence the underlying cause of infertility often remains obscure and untreated.³ It is observed that almost 20% of the infertility cases are solely due to a male factor.⁴ It is estimated that around 1% of total male population and 10% of men seeking infertility treatment are effected by testicular failure.⁵ In order to evaluate male infertility it is important to have a comprehensive history and physical examination along with semen analysis and hormonal assay. Other useful tests include anti-sperm antibodies, transrectal ultrasonography, vasography, genetic studies and hormonal profile but these tests are not always conclusive. Evaluation by testicular biopsy in cases of azoospermia or oligospermia provide reliable information regarding spermatogenesis which can further be categorized into various histopathological patterns.⁶ This provides a valuable information to the clinician for the purpose of prognosis and treatment.⁷ Spermatogenesis is the process of germ cell development and in males the germ cells develop in the seminiferous tubules from puberty till old age.⁸ In order to understand spermatogenesis a detailed information is required regarding the organization of the germinal epithelium of seminiferous tubules and structure and function of different types of germ cells.⁹ Diagnostic testicular biopsy is used to determine testicular histopathological patterns and to foresee the possibility of finding sperms in the testes.¹⁰

Introduction

Testicular biopsies represent the final outcome of a variety of testiculopathies which range from normal spermatogenesis indicating seminal tract obstruction or absence of vas deferens and is called obstructive azoospermia. A variety of problems with spermatogenic process itself is categorized as non obstructive azoospermia. Consequently when a testicular biopsy is properly interpreted, it can be a cornerstone upon which a male infertility specialist can formulate a treatment plan.¹¹ The major reproductive treatment option for many azoospermic men include In- vitro fertilization (IVF) and Intra cytoplasmic sperm injection (ICSI) for cases in which the sperm can be retrieved. Therefore histopathological testicular patterns have an important role in providing information regarding the presence of spermatozoa for ICSI in cases of non obstructive azoospermia because some individuals may show residual spermatogenic sites in the testes.¹⁰

Men that have non-obstructive azoospermia have either hypospermatogenesis, maturation arrest, Sertoli cell only syndrome or seminiferous tubule hyalinization on testicular biopsies. Previously it was assumed that men with non obstructive azoospermia are untreatable but in the early studies of quantitative analysis of spermatogenesis it was observed that azoospermic men with germinal failure often have minute foci of spermatogenesis.¹² Therefore testicular histopathological patterns are useful for further workup of infertile males and for the therapeutic sperm retrieval in assisted reproductive techniques.¹³ The aim of this study was to evaluate the histopathological pattern of testicular biopsy specimens from infertile males and to categorize each case according to Modified Johnson scoring system.

Materials and Methods

Testicular biopsy specimens received at private setups of two of the authors during a period of 2 years from June 2011- July 2013 were included in this study. All testicular biopsies either unilateral or bilateral were included in the study. All the testicular biopsies were received in 10% formalin fixative and routinely processed and stained with Hematoxylin and Eosin (H & E). Clinical data was obtained from patient's medical record and testicular biopsy slides were examined under the microscope. Various histopathological patterns were evaluated and categorized according to the Modified Johnson's scoring. One more thing noted was the histological uniformity within the same testis as well as between right and left testes. If more than one histological

pattern was noted in the same testicular biopsy it was called 'Mixed pattern'.³ If right and left testes showed different testicular pattern it was called 'Discordant pattern'.³

The testicular biopsies were categorized into different histopathological patterns¹⁴ as follows:

1. Normal Spermatogenesis: The seminiferous tubules are lined by thin basement membrane and the germinal epithelium shows normal progression from spermatogonia to spermatocytes along with spermatids and spermatozoas.
2. Hypospermatogenesis: The germinal epithelium shows all the stages of germ cells but the number is reduced.
3. Germ cell maturation arrest: At a specific cell stage the process of spermatogenesis is arrested usually at the level of primary or secondary spermatocytes.
4. Sertoli cell only syndrome: The tubules contain only Sertoli cells and no other cells of spermatogenesis.
5. Seminiferous tubule hyalinization: The tubules have much thickened basement membrane with a smaller diameter along with tubular collagenization. There is no germinal epithelium.
6. Mixed pattern: There is variation in the histopathological pattern in the same testicular biopsy
7. Discordant pattern: There is variation in the histopathological pattern of right and left testes.

The number of cases and their percentages for various histopathological patterns were calculated. In addition to categorizing the cases according to the histopathological patterns, they were also graded according to the Modified Johnson scoring system.¹⁵ According to this scoring system the testicular biopsies were further evaluated and given a score from 1 to 10. Modified Johnson scoring¹⁵ is given as follows:

- Score 10: There is full spermatogenesis
- Score 9: Incomplete spermatogenesis with many late spermatids
- Score 8: There are less than 5 spermatozoa per tubules and a few late spermatids
- Score 7: There are many early spermatids but no spermatozoa or late spermatids.
- Score 6: There are few early spermatids but no spermatozoa or late spermatids
- Score 5: there are many spermatocytes but no spermatozoas or spermatids

- Score 4: There are few spermatocytes but no spermatozoas or spermatids
- Score 3: There are only spermatogonias
- Score 2: Only presence of Sertoli cells and no germinal epithelial cells
- Score 1: There is no seminiferous epithelium

In each case the findings were recorded on a proforma.

Results

Total 53 cases of testicular biopsies from azoospermic males were evaluated. Their age ranged from 24 to 56 years with a mean age of 28 years. All the cases were categorized according to the above mentioned histopathological categories as shown in table 1. Most common histological pattern was of Sertoli cell only syndrome (30.18%) followed by Hypospermatogenesis seen in 18.86% cases.

Histopathological classification	No. of cases	%
Normal Spermatogenesis	09	16.98
Hypospermatogenesis	10	18.86
Germ cell maturation arrest	08	15.09
Sertoli cell only syndrome	16	30.18
Seminiferous tubule hyalinization	04	7.54
Mixed pattern	05	9.43
Discordant pattern	01	1.88

Mixed Histopathological patterns	No. of cases
Sertoli cell only syndrome - Germ cell maturation arrest	2
Seminiferous tubule hyalinization - Germ cell maturation arrest	1
Seminiferous tubule hyalinization - hypospermatogenesis	1
Hypospermatogenesis- Germ cell maturation arrest	1

There were 5 cases which showed mixed pattern as shown in table 2 and there was only 1 case showing discordant pattern. The histopathological patterns observed are shown in figures 1, 2, 3 and 4.

All the cases were further categorized according to the Modified Johnson scoring system and for the mixed pattern and discordant pattern cases the areas showing better histological patterns were selected for scoring in each case. Result of modified Johnson scoring is shown in Table 3.

Discussion

Male infertility is a reproductive health problem and it contributes to a significant number of cases of infertility. Due to various social reasons and stigma

Johnson scoring	N	%
10	5	9.4%
9	4	7.5%
8	5	9.4%
7	11	20.7%
6	2	3.7%
5	2	3.7%
4	0	0
3	1	1.8%
2	18	33.9%
1	5	9.4%

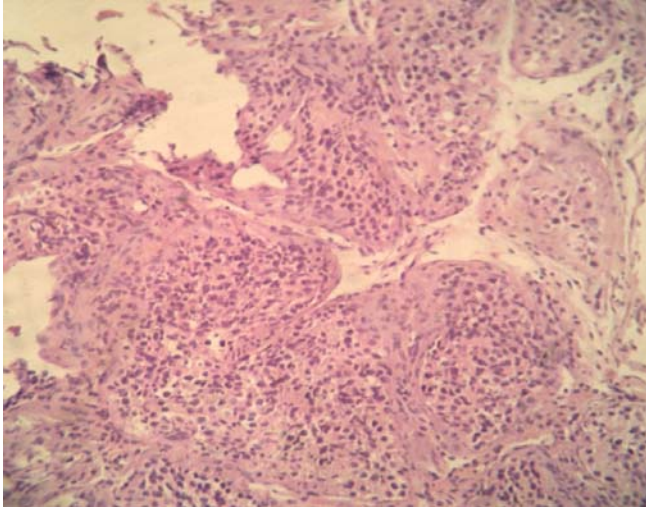


Fig 1: Showing Normal Spermatogenesis H&E x 100

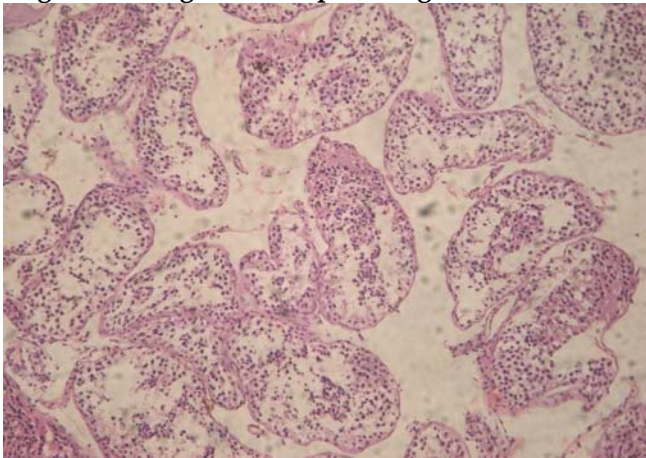


Fig 2: Showing Hypospermatogenesis H&E x 100

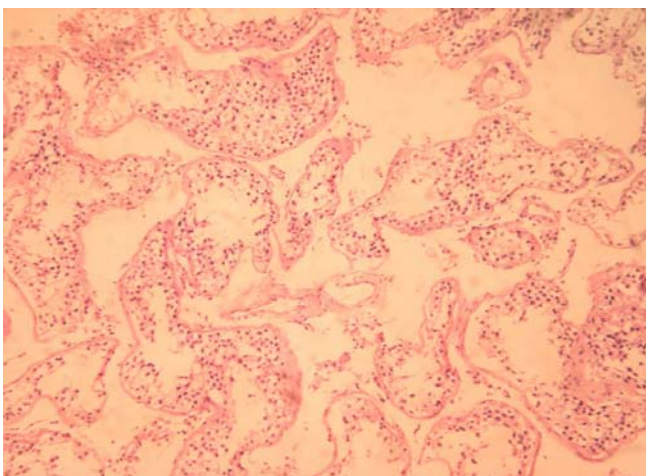


Fig 3: Showing pattern of Germ cell maturation arrest H&E x 100

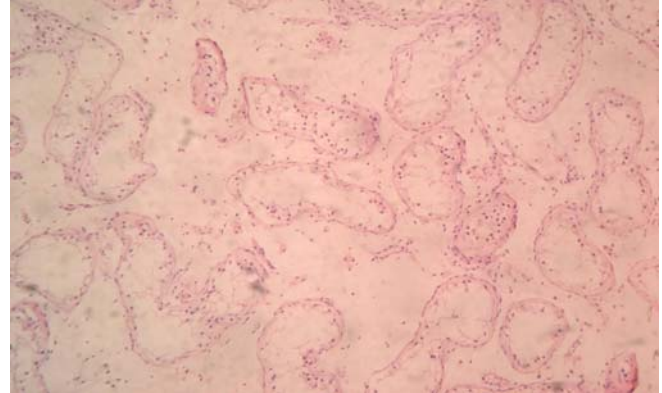


Fig 4: Showing pattern of Sertoli cell only syndrome H&E x 100

associated with it, this problem is poorly studied and often undertreated.¹⁶ The major causes of male infertility can be grouped as pre testicular, testicular and post testicular. The pre testicular causes include extragonadal endocrine disorders which lead to aberrant hormonal stimulation or suppression and as a result have an adverse effect on spermatogenesis. It includes cases of hypogonadotropic hypogonadism which can either be congenital Kallmann's syndrome or acquired due to trauma or tumors. These causes respond well to hormone replacement therapy.¹⁷ Other causes include various drugs that decrease FSH levels and sperm motility. Adopted life style such as cigarette smoking, chronic alcoholism and marijuana intake also have a role in infertility.¹⁸ The testicular causes are actually the primary defects of the testes such as congenital or some secondary disease. Congenital causes include Klinefelter's syndrome and Y-deletion and acquired causes are radiotherapy, chemotherapy, torsion and mumps orchitis. Testicular maldescent is also included in this category.¹⁷ Post testicular causes are the ones in which there is problem in ejaculation or there is a defect in the genital tract such as obstruction of vas deferens, lack of vas deferens, infections, hypospadias, ejaculatory duct obstruction or impotence.¹⁹ Men in this category undergo surgical reconstruction of ducts. This categorization of cause for infertility provides an intelligent basis to take corrective measures and to withhold therapy in those cases in which the biopsy indicates a poor or hopeless prognosis for fertility.¹¹ In the present study, 16.98% of cases showed normal spermatogenesis which indicates duct obstruction to be the cause of infertility. Amongst these 9.4% were of Johnson score 10 and 7.5% were of score 9. Rashed et al² also had 10% cases of score 10 but 14% were of

score 9. The results of Jamal and Mansoor are similar in which, cases of normal spermatogenesis were 15%.²⁰ Colgan et al reported 20%²¹ cases of normal spermatogenesis, Wong et al recorded 25%²² and Rashed et al recorded 24%.² In some studies there was a higher incidence of normal spermatogenesis such as 35% reported by Al-Rayess et al²³ and 38% by Thomas J.²⁴ In contrast a few studies showed very low incidence such as 5% by Meinhard et al.²⁵ It is important to differentiate between obstructive and non-obstructive azoospermia because obstructive azoospermia has a cost-effective treatment option such as microsurgical reconstruction of the obstructed ducts.

In this study hypospermatogenesis represented 18.8% of all cases and they were categorized as score 7 (20.7%). This result is similar to the results of some other studies such as a study by Thomas reported 19%²⁴ and Al-Rayess et al²³ reported 13% of cases. In cases of hypospermatogenesis there is a great chance of isolating viable and intact spermatozoa which are capable of fertilization and when mature spermatozoa are absent difficulties arise.²⁶ In our study this finding is low as compared to some studies which show high incidence such as a study by Haddad et al reported 55.8%²⁷ and Colgan et al²¹ reported 49%. Germ cell maturation arrest is usually due to genetic or some secondary influences such as due to some toxic substances (Antibiotics, chemotherapy or radiotherapy). It may also be due to some liver or kidney disease.²⁸ In this study the number of cases is low (15.09%) and they were further categorized from score 6-3. Similar results were seen in a study by Branner and Roth²⁹ who reported 12.5%, Golgen and Al-Rayess et al²³ reported 11%. There is great variation in the incidence of this finding among other studies as Haddad et al²⁷ reported only 1.7% whereas Glina et al¹⁰ reported 37.5% cases.

The most frequent histopathological pattern seen in this study was of Sertoli cell only syndrome that is 30% of cases and all were of score 2 (33.9%). This was similar to the result by Rashed et al² (34%) and Al-Rayess et al²³ (23.5%). SCOS can be due to multiple causes such as irradiation, cytotoxic drugs, cryptorchidism and even consanguinity.³⁰ In some studies the incidence was very low such as 8% was reported by Wong et al²² and Haddad et al²⁷ recorded only 2.9%. The last pattern observed was of tubular hyalinization which was noted in very few cases (7.5%) and they were all of score 1(9.4%). This result is

similar to that of Rashed et al², Meinhard et al²⁵ and Al-Rayess et al²³, all of them reported 6% of cases. High incidence was reported by Thomas (23%)²⁴ and Haddad et al (28.4%).²⁷ Another thing noted in this study was that there were 5 cases of mixed pattern and 1 case of discordant pattern. It is a common finding to have mixed as well as discordant pattern.³¹ This pattern was also noted in previous studies such as Abdullah and Bondagii³ noted 9 mixed patterns and 5 discordant pattern cases. McLachlan et al³¹ noticed a high frequency of hypospermatogenesis and mixed pattern. This finding indicates that always bilateral testicular biopsies should be performed instead of unilateral. In non-obstructive azoospermic males, histopathological patterns of testicular biopsies have a predictive role in the possibility of finding spermatozoa for ICSI, and therefore have great importance regarding the prognosis and treatment of male infertility.

Conclusion

In this study different histopathological patterns of testicular biopsies in male infertility were outlined in our setup and it was observed that Sertoli cell only syndrome was the most common pattern among the different studied patterns. Hypospermatogenesis was the second most common pattern. In this study it was also noted that there is variation in the histopathological patterns in the same testicular biopsy as well as in right and left testicular biopsies therefore careful examination of the testicular biopsies should be carried out and always bilateral testicular biopsies should be taken in azoospermic men to ascertain the accurate cause.

References

1. Gnoth C, Godehardt E, Frank-Herrmann P, et al. Definition and prevalence of subfertility and infertility. *Hum Reprod.* 2005; 20(5):1144-7.
2. Rashed MM, Ragab NM, Shalaby AR, Ragab WK. Patterns of testicular histopathology in men with primary infertility. *The Internet Journal of Urology.* 2008; 2(5):1-4.
3. Abdullah L, Bondagji N. Histopathological patterns of testicular biopsy in male infertility: A retrospective study from a tertiary care center in the western part of Saudi Arabia. *Urol Ann* 2011; 3:19-23
4. Thonneau P, Marchand S, Tallec A et al. Incidence and main causes of infertility in a resident population (1,850,000) of three French regions (1988-1989). *Hum Reprod* 1991; 6:811.
5. Wang C and Swerdloff RS. Evaluation of testicular function. *Baillieres Clin Endocrinol Metab.* 1992; 6(2):405-34.
6. Rosai J. Rosai and Ackerman's Surgical Pathology. Abdullah and Bondagji: Histopathological patterns of testicular biopsy in male infertility. 9th ed. Vol. 1. p.1260-5.

7. Male Infertility Best Practice Policy Committee of the American Urological Association; Practice Committee of the American Society for Reproductive Medicine. Report on optimal evaluation of the infertile male. *Fertil Steril.* 2006; 86(5 suppl):S202–S209.
8. Oshima S, Okayasu I, Uchima H et al. Histopathological and morphometrical study of the human epididymis and testis. *Acta Pathol Jpn.* 1984; 34(6):1327-42.
9. Holstein A, Schulze W and Davidoff M. Understanding spermatogenesis is a prerequisite for treatment *Reproductive Biology and Endocrinology* 2003,1:107 <http://www.rbej.com/content/1/1/107>
10. Glina S, Soares J, Nelson J et al. Testicular histopathological diagnosis as a predictive factor for retrieving spermatozoa for ICSI in non-obstructive azoospermic patients. *Int Braz J Urol.*2005; 31(4):338-41.
11. Cerilli et al. A practical approach to testicular biopsy interpretation. *Arch Pathol Lab Med.* 2010; 134: 1198
12. Silber S J and Johnson L. Are round spermatid injections of any clinical value? ROSNI and ROSI revisited *Human Reproduction* vol. 13 no. 3 pp. 509-523, 1998
13. Skakkebaek NE; Giwercman A; de Kretser D. Pathogenesis and management of male infertility *Lancet* v343, n8911 (June 11, 1994):1473
14. Nistal M, Paniagua R. Testicular biopsy. Contemporary interpretation. *Urol Clin North Am* 1999; 26:555-93.
15. Holstein A, Schulze W and Davidoff M. Understanding spermatogenesis is a prerequisite for treatment *Reproductive Biology and Endocrinology*2003,1:107 <http://www.rbej.com/content/1/1/107>
16. Sasagawa I, Yazawa H, Suzuki Y, et al. Reevaluation of testicular biopsies of males with nonobstructive azoospermia in assisted reproductive technology. *Arch Androl.* 2001; 46:79-83.
17. Sharif K. Reclassification of azoospermia: the time has come? *Hum Reprod* 2000; 15 (2): 237-238
18. Leibovitch I and Mor Y. *Eur. Urol.*, 2005; 47 (3): 277–86; discussion 286–287.
19. Olooto W. Infertility in male: risk factors, causes and management- A review. *J Microbiol. Biotech. Res* 2012; 2(4): 641-645
20. Jamal A, Mansoor I. Morphological profile of testicular biopsies associated with infertility. *Saudi Med J* 2001; 22 (11):992-994
21. Colgan TT, Bedard TC, Strawbudge HTG, Buckspan MB, Klotan PS. Reappraisal of the value of testicular biopsy in the investigation of infertility. *Fertil Steril* 1980; 33: 56.
22. Wong TW, Straus FH, Warner NE. Testicular biopsy in the study male infertility. I Testicular causes of infertility. II Post testicular causes of infertility. III Pretesticular causes of infertility. *Arch Path* 1973; 95: 151, 160. 1974; 98: 1.
23. Al-Rayess MM and Al-Rikabi AC. Morphologic patterns of male infertility in Saudi patients A University Hospital experience *Saudi Medical Journal* 2000; 21 (7): 625-628
24. Thomas JO. Histological pattern of testicular biopsies in infertile males in Ibadan, Nigeria. *East African Medical Journal* 1990; 67: 578-584.
25. Meinhard E, McRae CU, Chisholm GD : Testicular Biopsy in Evaluation of Male Infertility *British Medical journal*, 1973; 3:577-581
26. Paz G, Gamzu R AND Yavetz H. Diagnosis of Nonobstructive Azoospermia: The Laboratory Perspective *Journal of Andrology.* 2003; 24 (2)
27. Haddad FH, Omari AA, Malkawi OM, et al. Patterns of testicular cytology in men with primary infertility: any change since the Gulf War? *Acta Cytol.* 2004; 48(6):807-12.
28. Behre HM and Bergmann M. Primary Testicular Failure Chapter 6; November 17, 2003 ; <http://www.endotext.org/male/male6/maleframe6.htm>
29. Brannen GE and Roth RR. Testicular abnormalities of the subfertile male. *J Urol* 1979; 122: 757.
30. Carrara R , Yamasaki R, Mazucatto LF, et al. Somatic and germ cell cytogenetic studies and AZF microdeletion screening in infertile men. *Genet. Mol. Biol.*2004; 27 (4)
31. McLachlan RI, Rajpert-De Meyts E, Hoei-Hansen CE, de Kretser DM, Skakkebaek NE. Histological evaluation of the human testis-approaches to optimizing the clinical value of the assessment: Mini review. *Hum Reprod* 2007; 22:2-16.